

Zh. Olzhabayeva*, B. Abdullaeva, I. Zharkova, A. Tukpetova

Al-Farabi Kazakh National University, Almaty, Kazakhstan

**Corresponding author: zhanna.olzhabayeva1@gmail.com*

Study of changes in the histological structure of the gills of carp and zander living in lake Balkhash

The problem of adaptation and reactivity of an organism to various environmental factors is one of the central problems in theoretical and practical biology. At present, the attention of researchers is especially attracted by the issues of ecological adaptation. Morphological works that shed light on the corresponding structural and functional rearrangements of fish gills in connection with their ecology are still poorly understood. In particular, the issues of comparative morphological assessment of the adaptive responses of gas exchange organs have not been developed. The impact of the enterprises of the metal and mining complex is reflected in the tissues of the organs of fish. Thus, environmental factors, such as the accumulation of heavy metals in water, subject the fish body to a structural and functional rearrangement, thereby changing the normal tissue structure. In this regard, the purpose of the study was to study changes in the histological structures of the gills of carp and zander living in Lake Balkhash. Changes in the tissue structure of the gill arch of fish were in the form of emerging pathologies, the frequency of which was noted using a comparative analysis. For the implementation of this work, a histological, morphometric and statistical study of the tissues of the gills of the studied fish individuals was also carried out. The following pathological processes were observed in the structure of the gills of carp and zander: changes in the shape of secondary lamellae, hyperplasia of the gill epithelium, necrosis and edema of the respiratory epithelium, as well as foci of hemorrhages. The detected changes in the histological structures of fish gills indicate the impact of external environmental factors, one of which, in this article, is the accumulation of heavy metals in water. This study was carried out from a natural ecosystem, thus, literary sources are used to compare the data obtained.

Keywords: gills pathology, heavy metals, lamellae, hemorrhages, necrosis, hyperplasia, carp, zander.

Introduction

The intense impact of human impact on the environment leads to serious disturbances in the functioning of ecosystems [1]. A good example is Lake Balkhash, which belongs to the Ile-Balkhash basin, the territory of which has recently been subjected to high environmental stress due to anthropogenic and natural factors and, accordingly, requires regular monitoring of the environment. The most convenient method for ecomonitoring of aquatic ecosystems is the study of the morphological and histological characteristics of the internal organs of fish [2-4], which is able to reflect the dynamics of biotope destruction. The internal organs of fish are characterized by selective accumulation of xenobiotics [5], while substances that pollute ecosystems accumulate in organs such as gills, liver, endocrine glands, gastrointestinal tract and kidneys [6, 7]. A particularly sensitive organ in fish is the gills, which are responsible for respiration and maintenance of osmotic pressure and acid-base balance of body fluids [8]. They play an important role in the excretion of toxic metabolic products and in maintaining food drainage [9]. Since a large surface area of the gills is in contact with the external environment, they are sensitive to even minor chemical or physical changes in the environment and are a target organ for many pollutants [10, 11]. Water flowing through the gills exposes the organ to constant contact with toxic substances [12], which is expressed in morphological and histological changes in organ structures [13]. The most dangerous chemical pollutants include heavy metals, which, when they enter the body of fish, accumulate in the organs, causing pathological processes. In this regard, the purpose of the study is to study changes in the histological structures of the gills of the carp and zander of Lake Balkhash, which can be caused by heavy metals.

Experimental

The research material is common carp (*Cyprinus carpio*) and common zander (*Sander lucioperca*). For the study, fish was caught from 2 points of Lake Balkhash. From each point, 10 individuals of both sexes of carp and zander were taken. The total number of fish is 20.

For histological analysis, the gills of carp and zander were selected, caught on the western coast of Lake Balkhash, Almaty region, Zhambyl district, Ulken village (45°12'18"N 73°58'53"E) and Karaganda region,

Aktogay district, Torangylyk village (46°46'21"N 74°49'52"E) in spring (Fig. 1). The most important indicator of the quality of the habitat of hydrobionts is the degree of water purity in terms of the content of heavy metals. In this regard, heavy metals were determined in all collected water samples according to practical guidelines. The determination of HM was carried out after appropriate sample preparation on an MGA-915 MD atomic absorption spectrophotometer (St. Petersburg).

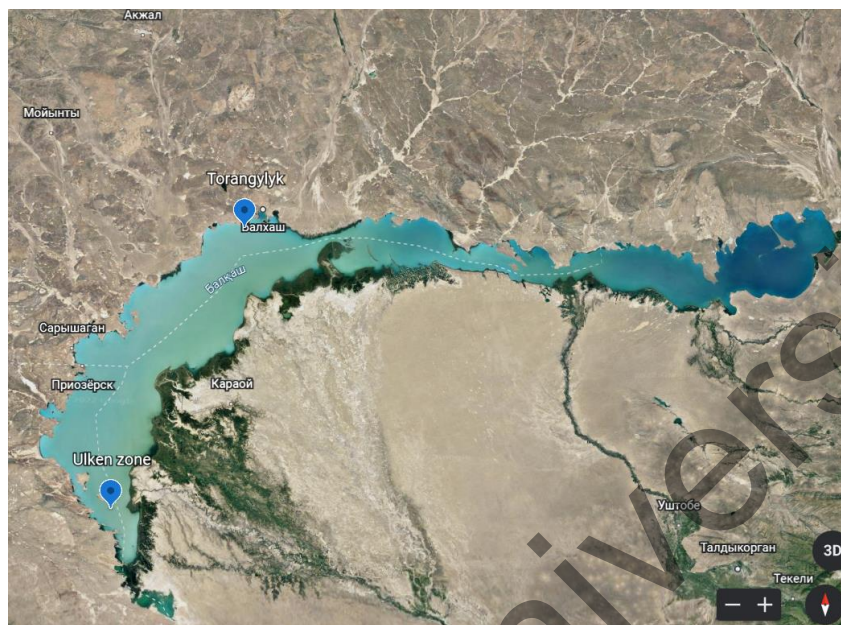


Figure 1. Points of catching fish of Lake Balkhash

The material for bio indicative research was processed and fixed in the field. For histological examination, fixation was carried out in 10% neutral formalin [14, 15]. Dehydration and compaction of the histological material was performed according to the standard technique [16, 17]. Sections were made on a rotary microtome with a thickness of no more than 4-5 μm . From gills, sections were made in the amount of at least 15 glass slides. Sections were stained with survey dyes, hematoxylin and eosin [18]. Histological preparations were analyzed under a Micros MC-20 light microscope. Digital micrographs were obtained using a Leica DMLB2 microscope with a Leica DFC 320 digital camera. Morphometric processing was carried out using the Bio Vision program, and statistical processing was carried out using Microsoft Excel.

Results and Discussion

In the studied individuals of carp and zander, the gills had a classical structure, and were represented by primary gill filaments, from which secondary gill filaments departed. A hyaline cartilaginous arch was located at the base of the gill filaments. The gill lobe was externally covered with primary gill epithelium, which consisted of several layers of squamous respiratory cells. In addition to respiratory cells, the primary gill epithelium contained rounded rod cells and numerous mucous cells. In most lamellae, edema of the primary gill epithelium was observed, the intensity of which was more pronounced in the basal layer (Fig. 2) and proliferation of respiratory cells, which often led to fusion of the secondary gill filaments. The secondary gill filaments in most individuals were curved and club-shaped. The basis of the secondary lobes was columnar cells, between which arterioles were located. Outside, the lamellae were covered with a single-layered squamous epithelium, among which there were large mucous cells. In addition, edema of the secondary gill epithelium was noted, and its exfoliation. In the gills, there was also a violation of the vascular bed in the form of vascular destruction, leading to the formation of extensive hemorrhages, and necrosis of the respiratory epithelium (Fig. 3). The incidence of detected pathological disorders of the gills is shown in Table 1. According to Table, most often in the gills of carp and zander caught in the Ulken zone, changes in the shape of lamellae were noted ($21.34 \pm 0.87\%$ and $22.21 \pm 0.66\%$ respectively). In individuals caught in the Torangylyk zone, extensive morphological changes were observed in the form of hyperplasia, which were found in $27.54 \pm 1.22\%$ of carp individuals and $24.12 \pm 0.87\%$ in zander. Among other pathologies, tissue necrosis was noted in the gills of carp and zander ($5.41 \pm 0.42\%$ and $4.75 \pm 1.36\%$ in the Ulken zone and

7.69 ± 0.27% and 8.72 ± 1.91 % in the Torangylyk zone), foci of hemorrhages (8.54 ± 0.92% and 6.47 ± 1.83% in the Ulken zone and 9.03 ± 0.82% and 7.96 ± 1.33% in the Torangylyk zone) and edema of the respiratory epithelium: 8.32 ± 0.77% and 8.91 ± 1.12% (Ulken zone) and 8.87 ± 0.43% and 9.14 ± 0.24% (Torangylyk zone). The revealed histopathological changes in the structure of the gills may well be associated with exposure to heavy metals in the water, the concentration of which is shown in Figure 3, 4. As follows from the data presented in Figure 2, an excess of MPC was found in 4 out of 6 studied HMs. From the results of this study, it can be seen that the excess of the MPC of heavy metals is distributed in the following order: Zn > Cu > Pb > Cd.

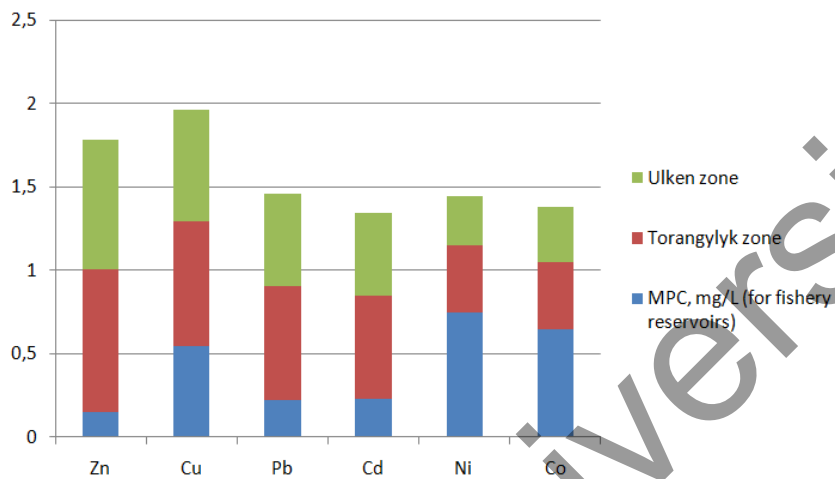


Figure 2. HM content in the water of Lake Balkhash: Ulken and Torangylyk zones

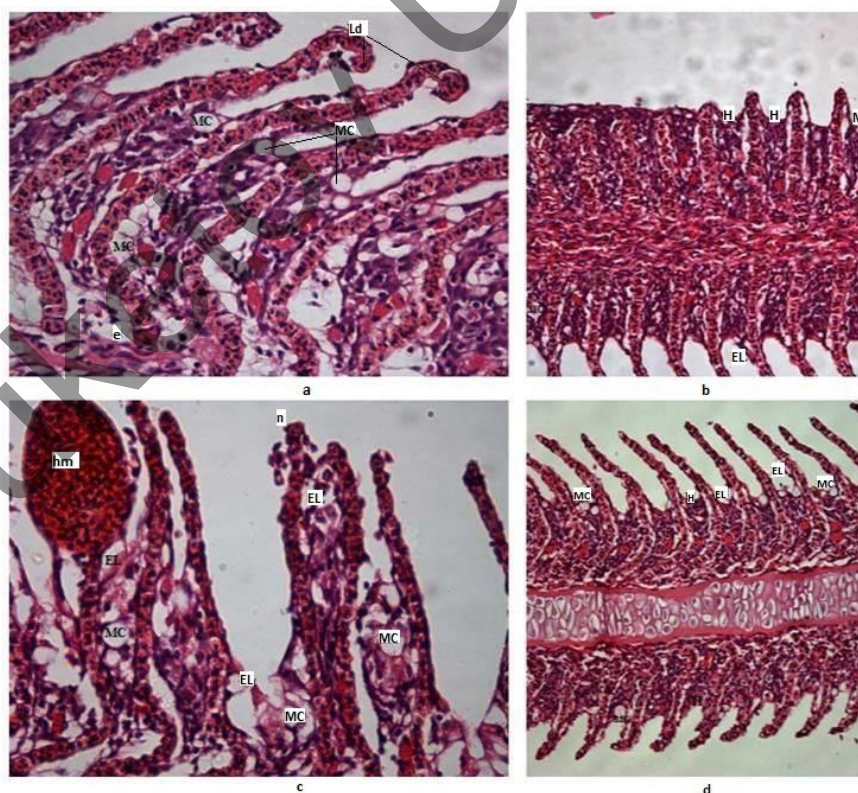


Figure 3. Carp gills. Stained with hematoxylin and eosin. A, B – Ulken Zone; C, D – Torangylyk Zone. a, c – 40×; b, d – 20×. MC – mucous cells, LD – lamella deformation, n – necrosis, EL – epithelial lifting, hm – hemorrhagic foci, e – edema, H – hyperplasia

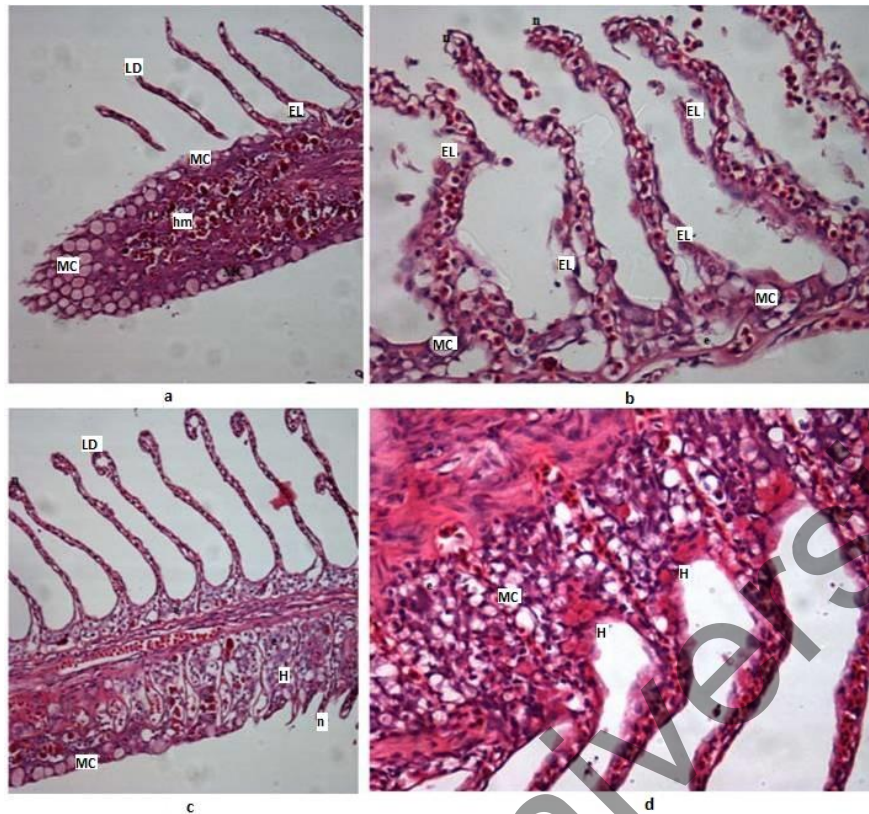


Figure 4. Zander gills. Stained with hematoxylin and eosin. A, B – Ulken Zone; C, D – Torangylyk Zone. a, c – 20×; b, d – 40×. MC – mucous cells, LD – lamella deformation, n – necrosis, EL – epithelial lifting, hm – hemorrhagic foci, e – edema, H – hyperplasia

T a b l e

The frequency of pathologies of the gills of carp and zander living in Lake Balkhash

Types of pathology	The frequency of gill pathologies in carp, %		The frequency of gill pathologies in zander, %	
	Ulken zone	Torangylyk zone	Ulken zone	Torangylyk zone
Deformation of the lamellae of the secondary epithelium	21.34 ± 0.87	23.11 ± 0.92	22.21±0.66	23.43 ± 0.87
Hyperplasia of the gill epithelium	19.62 ± 1.72	27.54 ± 1.22	18.51 ± 1.16	24.12 ± 0.87
Necrosis	5.41 ± 0.42	7.69 ± 0.27	4.75 ± 1.36	8.72 ± 1.91
Edema of the respiratory epithelium	8.32 ± 0.77	8.87 ± 0.43	8.91 ± 1.12	9.14 ± 0.24
Foci of hemorrhage	8.54 ± 0.92	9.03 ± 0.82	6.47 ± 1.83	7.96 ± 1.33

The number of fish that did not have violations of the structure of the gills was 13.01 % among carp and 12.52% in zander. Thus, a histological study of the gills showed changes in the shape of the lamellae, hyperplasia and edema of the respiratory epithelium, necrosis and foci of hemorrhage, some pathomorphological changes, in particular, hyperplasia, necrosis, microcirculatory disorders were noted in the organs of freshwater fish living in the Ile-Balkhash basin in works of Nurtazin S.T. and Salmurzauly R. et al. [19].

The obtained results indicate the impact of heavy metals on the ecosystem of Lake Balkhash.

Conclusions

The conducted research allowed drawing the following conclusions:

1. The following pathological processes were identified in the gills of carp and zander: change in the shape of the lamellae of the secondary epithelium, hyperplasia of the gill epithelium, necrosis and edema of the respiratory epithelium, as well as foci of hemorrhages, the total frequency of which was 71.74% in carp individuals and 62.25% in zander caught in the Ulken zone and 79.85% in carp and 68.75% in zander caught in the Torangylyk zone.

2. A comparative analysis showed that the percentage of frequency of pathologies in fish living in the Torangylyk zone is higher than in fish living in the Ulken zone. This is due to the fact that the concentration of heavy metals in the Torangylyk zone is higher than in the Ulken zone.

This scientific work can be used for further monitoring studies in order to bioindicate the state of aquatic ecosystems in the Ile-Balkhash basin.

Список литературы

- 1 Жапарова С.Б. Оценка экологического состояния малых водоемов Акмолинской области / С.Б. Жапарова, Ж.К. Хамидуллина // Вестн. Омск. регион. ин-та. — 2017. — № 1. — С. 129–134.
- 2 Суюнова А.Б. Экологический мониторинг загрязнения ихтиофауны нефтепродуктами и тяжелыми металлами Казахского сектора Каспийского моря / А.Б. Суюнова, М.В. Заболотных // Вестн. Краснояр. гос. аграр. ун-та. — 2016. — № 5. — С. 83–90.
- 3 Минеев А.К. Морфофункциональные изменения у *Abramis brama* Саратовского водохранилища / А.К. Минеев // Вопросы рыболовства. — 2015. — № 3. — С. 332–350.
- 4 Грушко М.П. Состояние жизненно важных органов судака Волго-Каспийского бассейна / М.П. Грушко, Н.Н. Фёдорова, М.Н. Насиханова // Вестн. Астрахан. гос. техн. ун-та. Сер. Рыбное хозяйство. — 2013. — № 3. — С. 108–112.
- 5 Гилева Т.А. Содержание тяжелых металлов в органах и тканях рыб, обитающих в разнотипных водоемах Пермского края / Т.А. Гилева, Е.А. Зиновьев, Н.В. Костицына // Аграрный вестн. Урала. — 2014. — № 8 (126). — С. 73–77.
- 6 Федорова Н.Н. Патоморфологические изменения жизненно важных органов волжских рыб / Н.Н. Федорова, М.П. Грушко, Н.А. Каниева // Вестн. Астрахан. гос. техн. ун-та. Сер. Рыбное хозяйство. — 2019. — № 4. — С. 104–109.
- 7 Клишин А.Ю. Морфофункциональные изменения ламелл и филламентов жабр щуки (*Esox lucius*) / А.Ю. Клишин // Общество и цивилизация в 21 веке: тенденции и перспективы развития. — 2014. — С. 25–29.
- 8 Минеев А.К. Морфофункциональные изменения у *Abramis brama* Саратовского водохранилища / А.К. Минеев // Вопросы рыболовства. — 2015. — Т. 16, № 3. — С. 332–350.
- 9 Костицына Н.В. Характеристика морфологических параметров респираторной поверхности жабр обыкновенного пескаря *Gobio gobio* (L.) из разнотипных водоемов Пермского края / Н.В. Костицына, О.П. Кузьменко // Вестн. Перм. ун-та. Сер. Биология. — 2011. — № 1. — С. 68–72.
- 10 Васильева О.Б. Оценка перекисного окисления липидов в тканях рыб изозер системы реки Кенти, Республика Карелия / О.Б. Васильева, М.А. Назарова, Н.Н. Немова // Труды Карел. науч. центра РАН. — 2020. — № 3. — С. 87–94.
- 11 Крамар К.В. Содержание ртути в органах и тканях рыб / К.В. Крамар // Символ науки: Междунар. науч. журн. — 2017. — № 4(3). — С. 18–21.
- 12 Ковековдова Л.Т. Микроэлементы (As, Cd, Pb, Fe, Cu, Zn, Se, Hg) в промысловых ракообразных Японского моря / Л.Т. Ковековдова, И.С. Наревич // Изв. ТИНРО. — 2017. — Т. 189. — С. 147–155.
- 13 Бикташева Ф.Х. Оценка риска по тяжёлым металлам в организме представителей ихтиофауны озера Асылыкуль / Ф.Х. Бикташева // Изв. Оренбург. гос. аграр. ун-та. — 2009. — № 4 (24). — С. 184–186.
- 14 Ромейс Б. Микроскопическая техника. — М.: Изд-во ин. лит., 1957. — 719 с.
- 15 Роскин Г.И. Микроскопическая техника / Г.И. Роскин, Л.Б. Левинсон. — М.: Сов. наука, 1957. — 234 с.
- 16 Martoja R. Unitition aux techniques de l'histologie animal / R. Martoja, U. Martoja-Pierson. — Paris: Masson, 1967. — 345 p.
- 17 Саркисов Д.С. Микроскопическая техника. Руководство для врачей и лаборантов / Д.С. Саркисов, Ю.Л. Перов. — М.: Медицина, 1996. — 544 с.
- 18 Нуртазин С.Т. Морфологическое исследование внутренних органов отдельных видов рыб, обитающих в реке Иле в районе плотины / С.Т. Нуртазин, С.С. Кобегенова, И.М. Жаркова, О.А. Решетова // Вестн. Казах. нац. ун-та. Сер. экол. — 2011. — № 3 (32). — С. 202–208.
- 19 Салмурзаулы Р. Экосистемы дельты реки Иле. Современное состояние и тенденции изменений: моногр. / Р. Салмурзаулы, С.Т. Нуртазин, М.К. Икласов, И.М. Жаркова. — Алматы: Казак университеті, 2018. — С. 156, 157.

Ж. Олжабаева, Б. Абдуллаева, И. Жаркова, А. Тукпетова

Балқаш көлінде мекендейтін сазан және көксерке желбезектерінің гистологиялық құрылысындағы өзгерістерді зерттеу

Организмнің әртүрлі сыртқы орта факторларына бейімделуі мен реактивтілігі теориялық және практикалық биологияның маңызды мәселелерінің бірі. Экологиялық бейімделу сұрақтары қазіргі зерттеушілердің назарын ерекше аудартады. Балық желбезектерінің қоршаған орта экологиясына байланысты құрылымдық және функционалдық бейімделулері жайында жарық көрген морфологиялық жұмыстар әлі де аз. Атап айтқанда, газ алмасу органдарының бейімделу реакцияларын салыстырмалы морфологиялық бағалау жұмыстары жазылмаған. Металл-кен өндіру кешені кәсіпорындарының әсері балық мүшелерінің ұлпаларына әсер етеді. Бұл кәсіпорындардан келіп түскен ауыр металдар суда жинақталып, балық организмін құрылымдық және қызметтік өзгерістерге ұшыратады, осылайша қалыпты ұлпа құрылысы бұзылады. Осыған байланысты зерттеу жұмысының мақсаты Балқаш көлінде мекендейтін сазан және көксерке желбезектерінің гистологиялық құрылымдарындағы өзгерістерді анықтау. Балықтардың желбезек доғасының ұлпалық құрылымының өзгерістері патологиялық процестер түрінде көрінді, ал патологиялық процестер жиілігі салыстырмалы талдаудың көмегімен талданды. Сонымен қатар, жұмыстың мақсатына жету үшін зерттелген балық үлгілерінің желбезек ұлпаларына гистологиялық, морфометриялық және статистикалық зерттеу жүргізілді. Сазан мен көксеркенің желбезек құрылымында келесі патологиялық процестер: екінші реттік ламеллалар пішінінің өзгеруі, желбезек эпителийінің гиперплазиясы, тыныс алу эпителийінің некрозы мен ісінуі, қан кету ошақтары байқалды. Балық желбезектерінің гистологиялық құрылымдарындағы анықталған өзгерістер сыртқы орта факторларының әсерін көрсетеді, олардың бірі осы мақалада талданған суда ауыр металдардың жиналуы болып табылады. Берілген зерттеу жұмысы табиғи экожүйеден жүргізілді, сондықтан алынған мәліметтерді салыстыру үшін әдебиет көздері пайдаланылған.

Кілт сөздер: желбезек патологиясы, ауыр металдар, ламелла, қан кетулер, некроз, гиперплазия, сазан, көксерке.

Ж. Олжабаева, Б. Абдуллаева, И. Жаркова, А. Тукпетова

Изучение изменений гистологической структуры жабр сазана и судака, обитающих в озере Балхаш

Проблема адаптации и реактивности организма к разнообразным факторам внешней среды является одной из центральных в теоретической и практической биологии. В настоящее время внимание исследователей особенно привлекают вопросы тканевой адаптации. Морфологические работы, освещающие соответствующие структурно-функциональные перестройки жабр рыб в связи с их экологией, остаются еще мало изученными. В частности, не разработаны вопросы сравнительной морфологической оценки адаптивных реакций органов газообмена. Воздействие предприятий металло- и горнодобывающего комплекса отражается на организме рыб. Таким образом, экологические факторы, как накопление тяжелых металлов в воде подвергают организм рыб в структурно-функциональную перестройку, тем самым изменяя нормальную картину ткани. В связи с этим цель проводимого исследования заключалась в изучении изменения гистологических структур жабр сазана и судака, обитающих в озере Балхаш. Изменения тканевой структуры жаберной дуги рыб было в виде возникших патологий, встречаемость которых было отмечена с помощью сравнительного анализа. Для осуществления данной работы также было проведено гистологическое, морфометрическое и статистическое изучение тканей жабр исследуемых особей рыб. В структуре жабр сазана и судака наблюдались следующие патологические процессы: изменение формы вторичных ламелл, гиперплазия жаберного эпителия, некроз и отек респираторного эпителия, а также очаги кровоизлияний. Обнаруженные изменения в гистологических строениях жабр рыб свидетельствуют о воздействии внешних экологических факторов, одним из которых в настоящей статье является накопление тяжелых металлов в воде. Данное исследование осуществлялось из природной экосистемы, тем самым для сопоставления полученных данных привлекаются литературные источники.

Ключевые слова: патология жабр, тяжелые металлы, ламеллы, кровоизлияния, некроз, гиперплазия, сазан, судак.

References

- 1 Zhaparova, S.B. & Khamidullina, Zh.K. (2017). Otsenka ekologicheskogo sostoianii malykh vodoemov Akmolinskoi oblasti [Assessment of the ecological state of small water bodies of Akmolinsk region]. *Vestnik Omskogo regionalnogo instituta — Bulletin of Omsk regional institute*, 1, 129–134 [in Russian].
- 2 Suiunova, A.B. & Zabolotnykh, M.V. (2016). Ekologicheskii monitoring zagriazneniia ikhtiofauny nefteproduktami i tiazhelymi metallami Kazakhstanskogo sektora Kaspiiskogo moria [Environmental Monitoring of Pollution of Ichthyofauna with Petroleum Products and Heavy Metals of the Kazakh Sector of the Caspian Sea]. *Vestnik Krasnoyarskogo gosudarstvennogo agrarnogo universiteta RASGAU — Bulletin of the Krasnoyarsk State Agrarian University*, 5, 83–90 [in Russian].
- 3 Mineev, A.K. (2015). Morfofunktsionalnye izmeneniia u *Abramis brama* Saratovskogo vodokhranilishcha [Morphofunctional changes in *Abramis brama* of the Saratov reservoir]. *Voprosy rybolovstva — Fisheries issues*, 3, 332–350 [in Russian].
- 4 Grushko, M.P., Fedorova, N.N. & Nasikhanova, M.N. (2013). Sostoianie zhiznenno vazhnykh organov sudaka Volgo-Kaspiiskogo basseina [The state of vital organs of the walleye of the Volga-Caspian basin]. *Vestnik Astrakhanskogo gosudarstvennogo tekhnicheskogo universiteta. Seriya Rybnoe khoziaistvo — Bulletin of Astrakhan State Technical University. Series Fishery*, 3, 108–112 [in Russian].
- 5 Gileva, T.A., Zinovev, E.A. & Kostitsyna, N.V. (2014). Soderzhanie tiazhelykh metallov v organakh i tkaniakh ryb, obitaiushchikh v raznotipnykh vodoemakh Permskogo kraia [Heavy metal content in organs and tissues of fish living in different types of water bodies of the Perm Territory]. *Agrarnyi vestnik Urala — Agrarian Bulletin of Ural*, 8 (126), 73–77 [in Russian].
- 6 Fedorova, N.N., Grushko, M.P. & Kanieva N.A. (2019). Patomorfologicheskie izmeneniia zhiznenno vazhnykh organov volzhskikh ryb [Pathomorphological changes in vital organs of Volga fish]. *Vestnik Astrakhanskogo gosudarstvennogo tekhnicheskogo universiteta. Seriya Rybnoe khoziaistvo — Bulletin of Astrakhan State Technical University. Series Fishery*, 4, 104–109 [in Russian].
- 7 Klishin, A.Yu. (2014). Morfofunktsionalnye izmeneniia lamell i filamentov zhabr shchuki (*Esox lucius*) [Morphofunctional changes in the lamellae and filaments of pike gills (*Esox lucius*)]. *Obshchestvo i tsivilizatsiia v 21 veke: tendentsii i perspektivy razvitiia — Society and civilization in 21 century: tendency and prospects of development*, 25–29 [in Russian].
- 8 Mineev, A.K. (2015). Morfofunktsionalnye izmeneniia u *Abramis brama* Saratovskogo vodokhranilishcha [Morphofunctional changes in *Abramis brama* of the Saratov reservoir]. *Voprosy rybolovstva — Fisheries issues*, 16(3), 332–350 [in Russian].
- 9 Kostitsyna, N.V. & Kuzmenko, O.P. (2011). Kharakteristika morfologicheskikh parametrov respiratornoi poverkhnosti zhabr obyknovennogo peskaria *Gobio gobio* (L.) iz raznotipnykh vodoemov Permskogo kraia [Description of Morphological Parameters of Respiratory Surface of Gills of Common *Gudgeon Gobio* (L.) from Different Types of Water Bodies of Perm Krai]. *Vestnik Permskogo universiteta. Seriya Biologiia — Bulletin of Perm University. Series biology*, 1, 68–72 [in Russian].
- 10 Vasileva, O.B., Nazarova, M.A. & Nemova, N.N. (2020). Otsenka perekisnogo okisleniia lipidov v tkaniakh ryb iz ozer sistemy reki Kenti, Respublika Kareliia [Assessment of lipid peroxidation in fish tissues from lakes of the Kenti River System, Republic of Karelia]. *Trudy Karelskogo nauchnogo tsentra RAN — Proceedings of Karelia scientific center RAS*, 3, 87–94 [in Russian].
- 11 Kramar, K.V. (2017). Soderzhanie rtuti v organakh i tkaniakh ryb [Mercury content in fish organs and tissues]. *Simvol nauki: Mezhdunarodnyi nauchnyi zhurnal — Symbol of science: international scientific journal*, 4 (3), 18–21 [in Russian].
- 12 Kovekovdova, L.T. & Narevich, I.S. (2017). Mikroelementy (As, Cd, Pb, Fe, Cu, Zn, Se, Hg) v promyslovnykh rakooobraznykh Yaponskogo moria [Trace elements (As, Cd, Pb, Fe, Cu, Zn, Se, Hg) in commercial crustaceans of the Sea of Japan]. *Izvestiia TINRO — Proceedings of TINRO*, 189, 147–155 [in Russian].
- 13 Biktasheva, F.Kh. (2009). Otsenka riska po tiazhelym metallam v organizme predstavitelei ikhtiofauny ozera Asylykul [Risk assessment for heavy metals in the body of representatives of ichthyofauna of Lake Asylykul]. *Izvestiia Orenburgskogo gosudarstvennogo agrarnogo universiteta — Proceedings of Orenburg State Agrarian University*, 4 (24), 184–186 [in Russian].
- 14 Romeis, B. (1957). Mikroskopicheskaia tekhnika [Microscopic technique]. Moscow: Izdatelstvo inostrannoi literatury [in Russian].
- 15 Roskin, G.I. & Levinson, L.B. (1957). Mikroskopicheskaia tekhnika [Microscopic technique]. Moscow: Sovetskaia nauka [in Russian].
- 16 Martoja, R. & Martoja-Pierson, U. (1967). Unittion aux techniques de l'histologie animal. Paris: Masson, 1967.
- 17 Sarkisov, D.S. & Perov, Yu.L. (1996). Mikroskopicheskaia tekhnika. Rukovodstvo dlia vrachei i laborantov [Microscopic technique. Guidance for Physicians and Laboratory Technicians]. Moscow: Meditsina [in Russian].
- 18 Nurtazin, S.T., Kobegenova, S.S., Zharkova, I.M. & Reshetova, O.A. (2011). Morfoloicheskoe issledovanie vnutrennikh organov otdelnykh vidov ryb, obitaiushchikh v reke Ile v raione plotiny [Morphological study of the internal organs of certain fish species living in the river Ile in the dam area]. *Vestnik Kazakhskogo natsionalnogo universiteta. Seriya ekologicheskaiia — Bulletin of the National Kazakh University. Series environmental*, 3 (32), 202–208 [in Russian].
- 19 Salmurzauly, R., Nurtazin, S.T., Iklasov, M.K. & Zharkova, I.M. (2018). Ekosistemy delty reki Ile. Sovremennoe sostoianie i tendentsii izmenenii: monografiia [Ile River Delta ecosystems. Current State and Trends of Change: Monograph]. Almaty: Qazaq university, 156, 157 [in Russian].